

08/27/2013 5:18:48

SINUS RHYTHM

Abnormal P terminal force

POSSIBLE LEFT ATRIAL ABNORMALITY

QR complex in V1

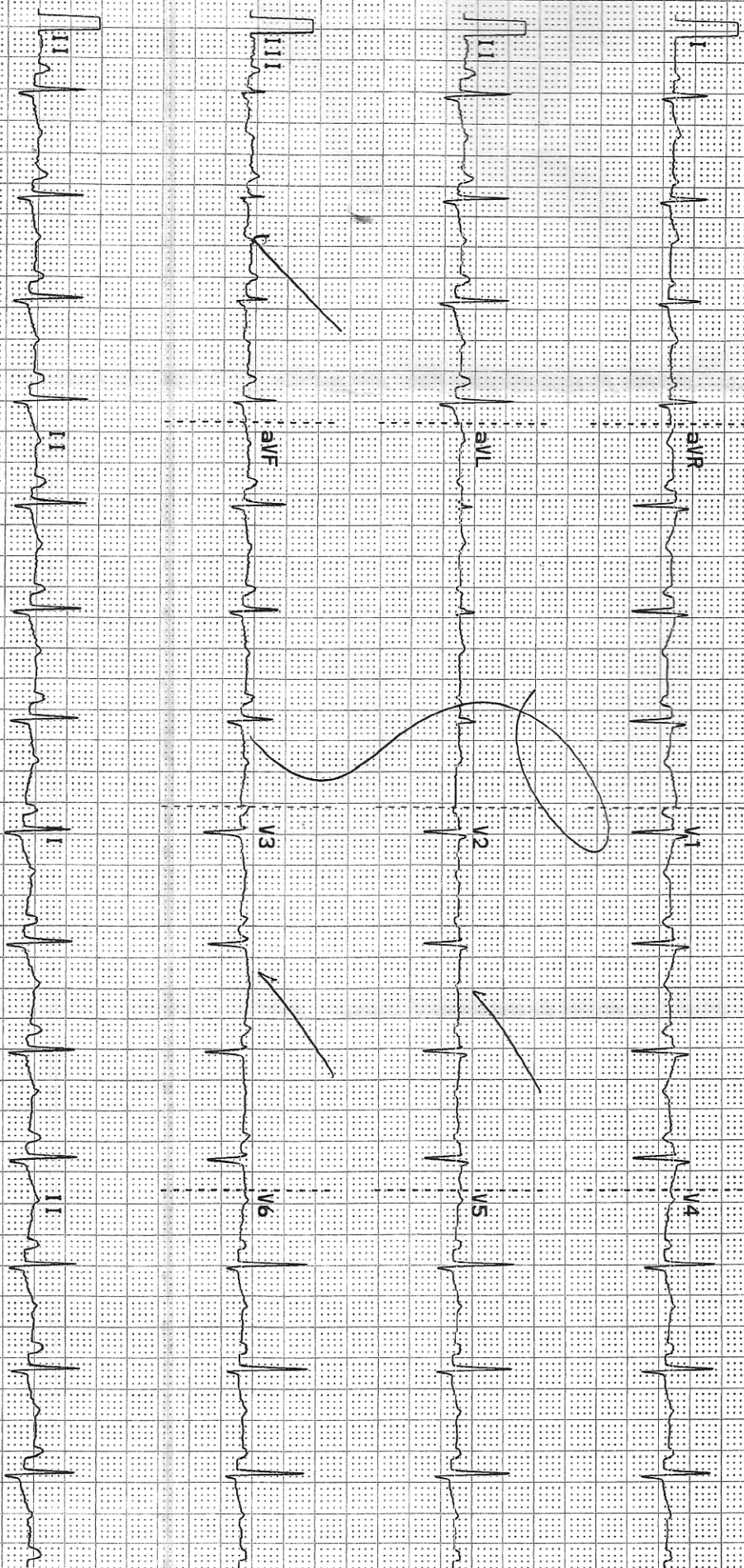
R' in V1

RIGHT VENTRICULAR HYPERTROPHY

Summary: ABNORMAL ECG

\* Unconfirmed Analysis \*

Vent. Rate:	86 bpm
RR Interval:	693 ms
PR Interval:	142 ms
QRS Duration:	78 ms
QT Interval:	356 ms
QTc Interval:	401 ms
QT Dispersion:	66 ms
P-R-T AXIS:	68° 47° 37°



ECG  
C 10 mm/mV

QTc=Hodges

Alpha 3000 Int ref 620950245 (0004)

Serial #: 92700-002459

25 mm/s  
STABLE 40 Hz