

05/21/2013 4:19:24

SINUS RHYTHM

rS' pattern in V1 or V2

PROBABLE NORMAL VARIANT

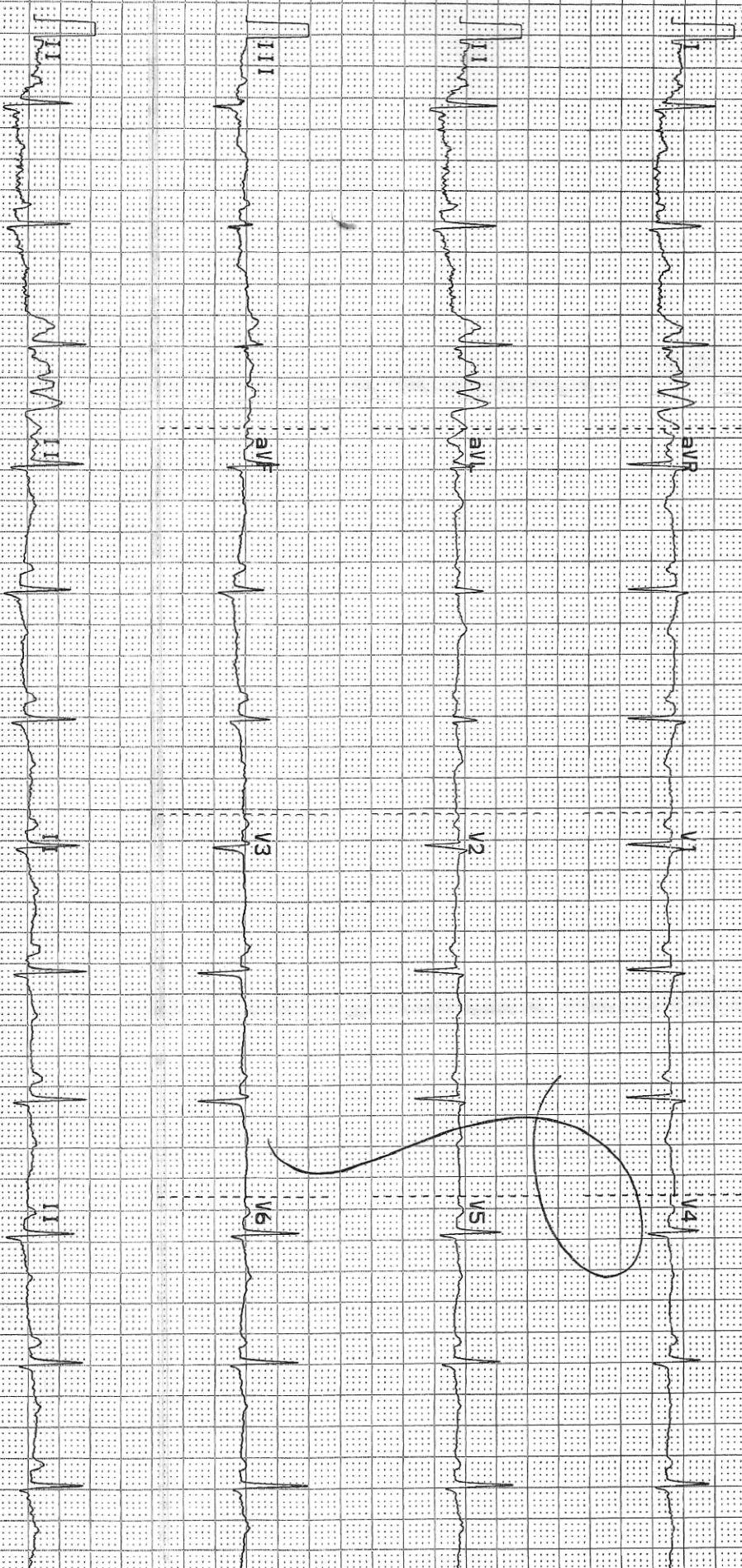
T wave changes in anterior leads

THESE MINOR CHANGES ARE OF EQUIVOCAL SIGNIFICANCE ONLY

Summary: BORDERLINE ECG

\* Unconfirmed Analysis \*

Vent. Rate:	73 bpm
RR Interval:	820 ms
PR Interval:	146 ms
QRS Duration:	84 ms
QT Interval:	368 ms
QTc Interval:	390 ms
QT Dispersion:	30 ms
P-R-T AXIS:	64° 28° 14°



mm/mV  
25 mm/s